

# Successful Treatment of Extensive Vitiligo with Monobenzone

**OLE MARTIN RORDAM, MD; ERIC WILLIAM LENOVEL, MD; MARTINE MAALO, MD**

St. Olav's Hospital, Trondheim, Norway

---

## ABSTRACT

Vitiligo is one of the most common dermatological disorders, appearing as one or more white macules or patches and affecting up to two percent of the population worldwide. The undesirable aesthetic properties of vitiligo, especially facial, may result in significant negative psychosocial effects, particularly a rate of depression twice that of the general population. While there is no cure, there are several treatment options, notably depigmentation in severe cases. Monobenzone is the most potent depigmenting agent. However, its use is limited due to the permanent and potent nature of the drug. This case presents an example of when timely and aggressive treatment with monobenzone is warranted, demonstrating excellent clinical response, which resulted in a significant increase in the quality of life in a patient with severe vitiligo. (*J Clin Aesthet Dermatol.* 2012;5(12):36–39.)

---

Vitiligo is among one of the most common dermatological disorders, affecting up to two percent of the population worldwide.<sup>1,2</sup> A chronic and usually progressive disorder, vitiligo presents discretely before 20 years of age, although first presentation in later life may occur as well.<sup>2</sup> Clinically, it appears as one or more well-circumscribed, hypopigmented, white macules or patches. This is due to the acquired autoimmune destruction of melanocytes, most often in areas of greater pigmentation, such as the face and dorsum of the hands where they are most exposed to UV radiation.<sup>2</sup> Apart from the cosmetic appearance, it is usually asymptomatic, although there is a greater tendency for sunburns and pruritis.<sup>2</sup>

The undesirable aesthetic properties of vitiligo, especially facial, may result in significant negative psychosocial effects, notably a rate of depression twice that of the general population.<sup>3</sup> In some cultures, vitiligo is not well understood. The depigmentation of vitiligo is thought to result from sexually transmitted infections, or of leprosy, and can have a damaging effect on educational, social, and employment opportunities.<sup>1,2,4</sup> Patients may feel embarrassed or ashamed of such a visible disorder. Studies have shown that vitiligo is associated with a greater burden of disease to patients, especially those in populations with dark skin.<sup>1,2,4</sup> Therefore, treatment, although not medically

necessary, provides large psychosocial gains for the patient, increasing their quality of life.

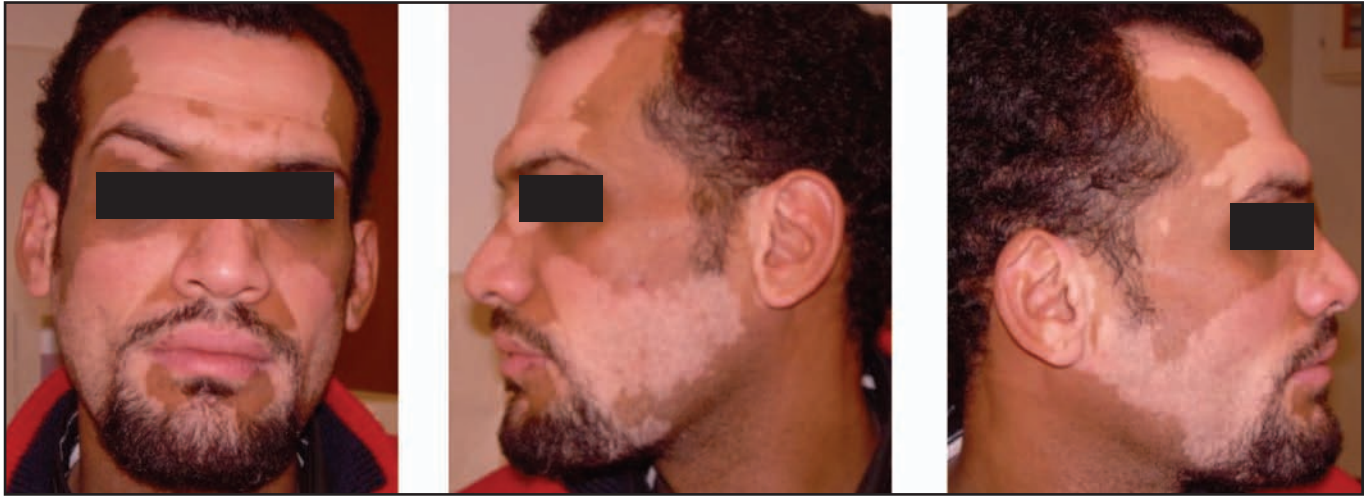There is no cure for vitiligo. Current treatment for vitiligo attempts to either increase or decrease pigmentation in order to achieve cosmetically pleasing results and increase the patient's self-esteem.<sup>5</sup> Repigmentation tends to require a prolonged treatment course and yield minimal positive results.<sup>6</sup> Strong topical steroids are generally the first line of treatment, with only a 50- to 75-percent repigmentation rate.<sup>5,6</sup> Tactrolimus, an immunosuppressive, and calcipotriene, a vitamin D analogue, are alternative topical repigmenting agents, with a similar efficacy as the topical steroids.<sup>6</sup> When such treatment fails, psoralen plus ultraviolet A radiation (PUVA) and narrow-band ultraviolet B radiation (NB-UVB) are effective alternatives.<sup>5,6</sup> However, PUVA can be carcinogenic and NB-UVB has low efficacy; both require prolonged treatments.<sup>5,7</sup> Alternative treatments exist, such as melanocyte transplantations. However, despite the type of treatment, repigmentation still remains difficult and time consuming, especially with advanced vitiligo.

Due to the difficulties with repigmentation, it is often easier to achieve depigmentation, especially when vitiligo affects more than 50 percent of the body.<sup>5-7</sup> It is, however, a more aggressive approach and its use is considered on an

---

**DISCLOSURE:** The authors report no relevant conflicts of interest.

**ADDRESS CORRESPONDENCE TO:** O Rordam, MD; E-mail: orordam@gmail.com



**Figure 1.** Patient prior to treatment. Note the significant symmetric depigmentation of the face.

individual basis because of the irreversible changes and increased sensitivity to sunburn of the treated areas. Several treatment modalities exist. Phenols, lasers, cryotherapy, and depigmenting systemic agents, such as imatinib, imiquimod, and diphencyprone, are often considered.<sup>7</sup> Monobenzone (monobenzyl ether of hydroquinone, MBEH) is usually the treatment of choice of depigmentation therapy for severe cases of vitiligo, and MBEH is usually used in concentrations of 20 to 40 percent to achieve the desired permanent depigmentation.<sup>5,7</sup> It achieves its effects by inducing the necrotic death of melanocytes.<sup>7</sup> Topical all-trans-retinoic acid (RA), a vitamin A derivative, causes mild depigmentation and when used in combination with MBEH, has synergistic effects, yielding depigmentation in a short amount of time.<sup>7</sup> Nair et al<sup>8</sup> have proposed that the RA enhances the absorption of monobenzone by melanocytes through the inactivation of their glutathione-dependent defense mechanisms.<sup>7,8</sup> Side effects of MBEH include skin irritation, contact dermatitis, ocular side effects, exogenous ochronosis, and difficulties in predicting response.<sup>5,9-11</sup> There can be repigmentation because of sun exposure or rarely as a reaction to the drug.<sup>5,7,10,11</sup> Due to these side effects, MBEH treatment can be somewhat controversial, and its use has been limited in some countries, such as the Netherlands, which has restricted it since 1990.<sup>7</sup> MBEH has been approved by the United States Food and Drug Administration since 1952 for permanent depigmentation of extensive vitiligo.

## CASE REPORT

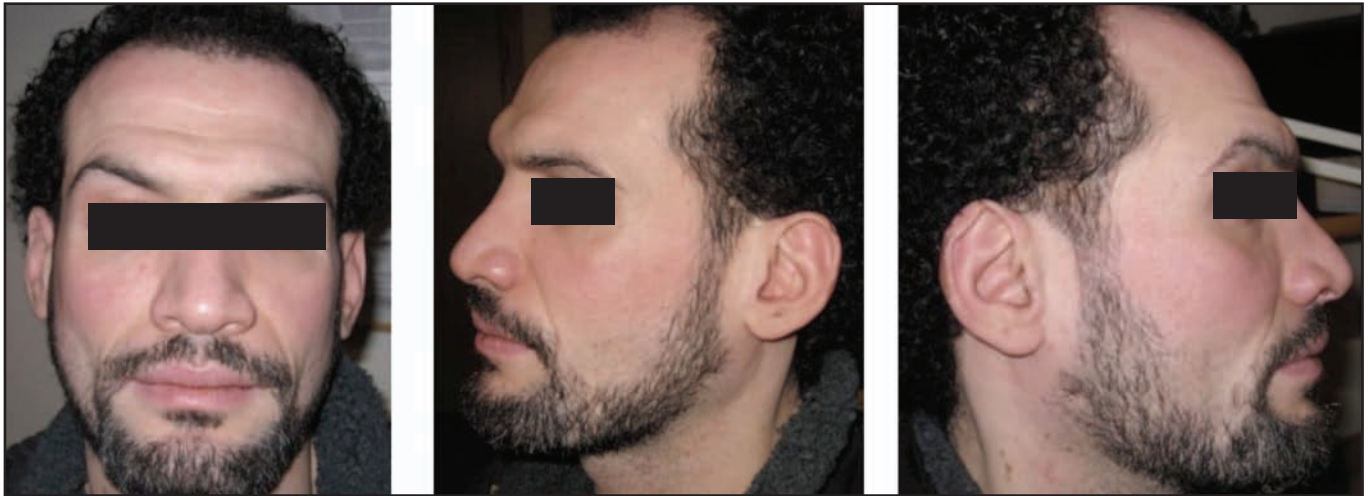
A 37-year-old African man with advanced vitiligo on the face, neck, trunk, and upper and lower extremities was referred for dermatological treatment for cosmetic reasons (Figure 1). The patient worked on-shore in the oil industry at the time of referral.

The onset of the vitiligo began at least 20 years prior to the consultation. Previously, the patient attempted to increase pigmentation through various treatment

modalities unsuccessfully. Treatment was attempted first with NB UVB and then later with several months of tacrolimus ointment 0.1% twice daily without any sign of improvement. The symptoms became much worse following his immigration to Norway one and a half years earlier, so he sought treatment. Most bothersome to the patient was that there were large areas of depigmentation on the face, which contrasts greatly with his naturally dark skin.

The patient first presented to clinic with slowly progressive, enlarging, bleached areas on the pectoral area, upper arms, legs, and face. Treatment aimed at increasing the blanching effect of the vitiligo. This was decided because the vitiligo was so advanced, depigmentation was determined to more likely be effective than repigmentation of the bleached areas. The first attempt at treatment was to allow the vitiligo to progress untreated in order to obtain as much depigmentation as possible. However, following six months, the vitiligo did not progress significantly, and the disfiguring effect of the depigmentation was still significant. The second attempt used a modified Pathak's formula, 4% hydroquinone with 0.1% tretinoin, daily in the evenings for 10 weeks. Results were inadequate following the 10 weeks. The third attempt of treatment used a compounded formulation of 20% monobenzone, which had to be prepared outside of Norway for this purpose. The patient applied it to pigmented areas of the face and neck once daily until desired results were noted. During this time, the patient was also instructed to wear sunblock while outdoors. Some slight skin irritation occurred after application of the cream, but no other side effects were noted. Hydrocortisone butyrate 0.1% cream (Locoid) was applied successfully for irritation.

Following the application of the 20% monobenzone cream, the patient achieved notable depigmentation. The treatment was continued more aggressively to try and match the treated areas with the bleached areas from the vitiligo. The cream was increased to twice daily for three



**Figure 2.** The patient following depigmentation with monobenzene. Note the uniform depigmentation throughout the face and neck.

and a half months after which depigmentation was extremely satisfactory, matching the bleached areas of vitiligo (Figure 2).

## DISCUSSION

The use of MBEH as a depigmenting agent dates back to the 1930's, where its effectiveness made it a very popular treatment for a wide range of pigment disorders.<sup>9</sup> However, in time, the many potential negative side effects quickly became apparent, especially its irreversible and erratic nature, and so its use since then has been limited.<sup>9,11</sup> Despite these negative side effects, its potential cosmetic and psychosocial benefits are significant and should always be taken into consideration when treating these patients, who may feel distressed and stigmatized by it.<sup>12</sup> A quick and effective treatment is important to ease the burden of disease from these patients and increase their quality of life.

The patient initially presented with a progressing vitiligo and was observed over six months in hopes that the depigmentation would be so great, no medical intervention would be necessary. The permanent nature of this treatment makes patient selection and screening important; however, in this case, the only worry was that the treatment would not work or that it would cause too much irritation. In this case, it worked very well without any significant irritation. Control three years later confirms a sustained and permanent depigmentation as well as a very satisfied patient.

The quick and effective results achieved with MBEH, following the ineffective 10-week trial of Pathak's formula, demonstrates the drug's effectiveness. However, side effects, such as skin irritation, contact dermatitis, ocular side effects, exogenous ochronosis, and permanent skin depigmentation have limited its use.<sup>5,9,11,12</sup> There is also a lack of recent clinical studies following the effects of various concentrations of MBEH therapy. Becker et al<sup>11</sup> conducted one of the most thorough studies to date on MBEH and found the responses to MBEH erratic. Twenty-five percent of their patients experienced no side effect from MBEH

treatment, several patients developed hyperpigmentation, and in some patients, the depigmentation occasionally spread from the treatment site following cessation of treatment.<sup>11</sup> More modern investigations into the rate of side effects of MBEH treatment at various concentrations are needed to better assess the benefit-risk ratio and help guide its use in the modern clinical setting.

This case highlights the importance of timely aggressive treatment of vitiligo and its effect on the patient's quality of life. Physicians should not have to shy away from prescribing the more potent treatments, due to the significant negative psychosocial impact vitiligo can have. A generally accepted psychosocial questionnaire and a modern study investigating the rates of side effects of MBEH would allow the development of a patient benefit-risk index, which could help both patients and physicians determine if MBEH treatment is appropriate for their individual cases.

## REFERENCES

1. Taïeb A, Picardo M; VETF Members. The definition and assessment of vitiligo: a consensus report of the Vitiligo European Task Force. *Pigment Cell Res.* 2007;20(1):27–35.
2. Alikhan A, Felsten LM, Daly M, Petronic-Rosic V. Vitiligo: a comprehensive overview Part I. Introduction, epidemiology, quality of life, diagnosis, differential diagnosis, associations, histopathology, etiology, and work-up. *J Am Acad Dermatol.* 2011 Sep;65(3):473–491.
3. Yamamoto Y, Tanioka M, Hayashino Y, et al. Application of a two-question screening instrument to detect depressive symptoms in patients with vitiligo: a pilot study. *J Am Acad Dermatol.* 2011 May;64(5):e69–e70.
4. Linthorst Homan MW, Spuls PI, de Korte J, et al. The burden of vitiligo: patient characteristics associated with quality of life. *J Am Acad Dermatol.* 2009 Sep;61(3):411–420.
5. Felsten LM, Alikhan A, Petronic-Rosic V. Vitiligo: a comprehensive overview Part II: treatment options and approach to treatment. *J Am Acad Dermatol.*

- 2011;65(3):493–514.
6. Mouzakis JA, Liu S, Cohen G. Rapid response of facial vitiligo to 308nm excimer laser and topical calcipotriene. *J Clin Aesthet Dermatol*. 2011;4(6):41–44.
  7. AlGhamdi KM, Kumar A. Depigmentation therapies for normal skin in vitiligo universalis. *J Eur Acad Dermatol Venereol*. 2011;25(7):749–757.
  8. Nair X, Parab P, Suhr L, Trampusch KM. Combination of 4-hydroxyanisole and all-trans retinoic acid produces synergistic skin depigmentation in swine. *J Invest Dermatol*. 1993;101(2):145–149.
  9. Mosher DB, Parrish JA, Fitzpatrick TB. Monobenzyloether of hydroquinone. A retrospective study of treatment of 18 vitiligo patients and a review of the literature. *Br J Dermatol*. 1977;97(6):669–679.
  10. Gupta D, Kumari R, Thappa DM. Depigmentation therapies in vitiligo. *Indian J Dermatol Venereol Leprol*. 2012;78(1):49–58.
  11. Becker S, Spencer MC. Evaluation of monobenzone. *JAMA*. 1962;180:279–284.
  12. Parsad D. Vitiligo: emerging paradigms. *Indian J Dermatol Venereol Leprol*. 2012;78(1):17–18. ●